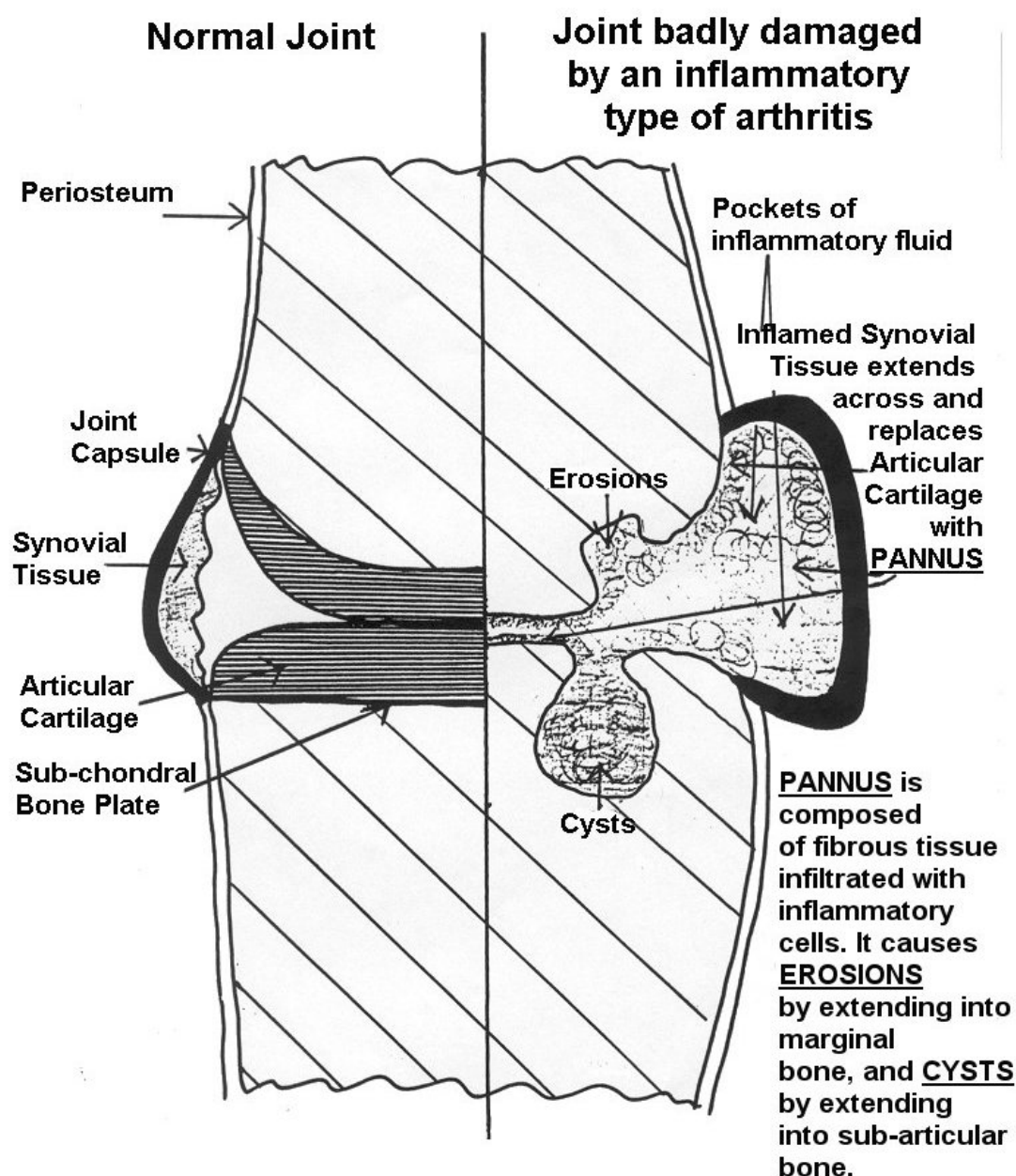


Diagram of a typical synovial joint



For further information about the Trust, visit our website www.royalberkshire.nhs.uk

West Berkshire Rheumatology Unit

Reviewed: December 2018

Review due: December 2020